

IMAGE ENHANCEMENT FOR CLINICAL CARDIAC ANGIOGRAM

¹BIJITH P S, ²DEEPA T

^{1,2}Department of electronics and communication engineering, Cochin College Of Engineering And Technology, Valancheri

ABSTRACT

The cardiac X ray angiogram images are very much important for the diagnosis of cardiac images. The delineation of blood vessels in medical images is an essential step in the computer aided diagnosis of cardiac vessels diseases. The noise content in the angiographic images make it harder for analysis. In this paper we discuss different image filtration methods in order to detect the vascular map for the real clinical angiograms.

INTRODUCTION

An angiogram is an X-ray test that uses a special dye and camera to take pictures of the blood flow in artery (such as the aorta) or vein such as the vena cava. An angiogram can be used to look at the arteries or veins in the brain, arms, heart, leg, back or belly.

A coronary angiogram is a procedure that uses X-ray imaging to see heart's blood vessels. The test is usually done to see whether there is a restriction for blood flow to the heart. Coronary angiogram is a part of general group of procedures known as cardiac catheterization. Cardiac catheterization procedures can diagnose and treat heart as well as blood vessel conditions. Coronary angiogram is the most common type of cardiac catheterization procedure. During coronary angiogram, a type of radio opaquedye that's visible by an X-ray machine is injected into the blood vessels of human heart. The X-ray machine rapidly takes a series of images (clinical angiograms), offering a look at the blood vessels

Angiography is the gold standard technique used to evaluate abnormalities or at deposition occurred in blood vessels, providing images with good spatial and temporal resolution. In digital images, the image processing filtration techniques can be easily used. The simplest methods

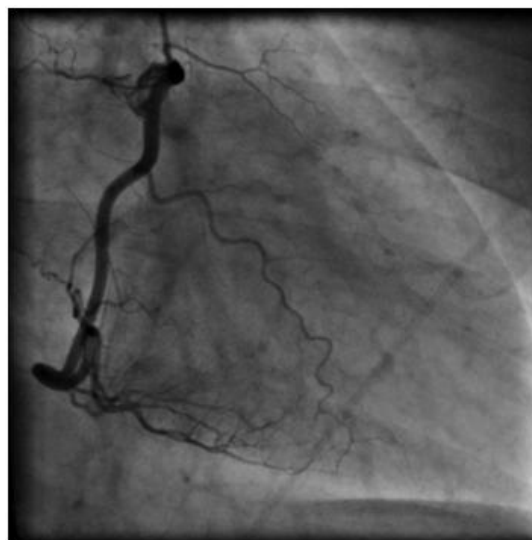

Figure 1 clinical angiogram

include the thresholding and the histogram operations which imply human intervention. The automatic approaches are difficult to implement due to different vessel scales and organ shadows.

I. MATERIALS AND METHODS

In this paper we have digital subtraction angiography in its linear and logarithmic version and more complicated nonlinear filtering such as Gabor and Frangi vessel filters which includes histogram operations together with Hessian-based method for delineating the vascular map of clinical images and thresholding. Matlab R2014a is used as the implementation software

II. GABOR FILTER

The Gabor filter use the directionally selective band pass filters which are successfully applied for orientated line detection. The multiscale version offers a possibility to be adapted for different frequencies. By tuning these filter frequencies, the noise is eliminated and the vessel centerline is enhanced, making the method ideal for the low contrast images with a blurring background . In the image complement, the vessels have positive contrast so they are brighter than background and need only the real kernel.

The function of real Gabor filter kernel oriented in the angle ϕ ,

$\phi = -\pi/2$ is $g(x,y)$;

$$g(x,y) = \frac{1}{2\pi S_x S_y} \exp \left\{ -\frac{1}{2} \left[\left(\frac{x}{S_x} \right)^2 + \left(\frac{y}{S_y} \right)^2 \right] \right\} \cdot \cos(2\pi \theta x)$$

Where θ is the central spatial frequency, S_x and S_y control the spatial expending horizontally and vertically related to frequency and the orientation band, S_x/S_y is the aspect ratio that is a measure of the filter's asymmetry.




Figure 2gabor filtered image

III. FRANGIS VESSELNESS FILTER

Frangi proposed an enhancement filter based on analysis of the eigenvalues of the Hessian matrix of the intensity image(coronary artery). Every element of the matrix is constructed with the aid of second-order Gaussian derivatives which offers the possibility to measure the contrast in the direction of the derivative between the image regions outside and inside the scale range

Given as $(-s, s)$

$$HG = \begin{bmatrix} h_{xx} & h_{xy} \\ h_{yx} & h_{yy} \end{bmatrix}$$

Where subscripts indicate the image gradients and h_{xy} is the convolution of the image J with the scaled version of the second-order Gaussian derivative $g(x,s)$:

$$G(x,s) = \frac{1}{2\pi s^2} e^{-\left(\frac{x^2}{2s^2}\right)}$$

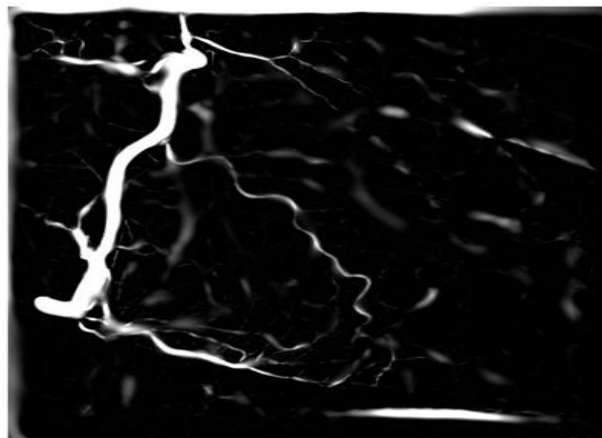


Figure 3 image enhancement using Frangis filter

IV .CONCLUSION

By digital image processing , image subtraction ,image filtration and thresholding we were able to reduce the noise effects in coronary artery angiogram image . theFrangis filter image provided the more detailed less noisy format. The digital subtraction angiography eliminates the unwanted background structures and produces an output image with the blood vessels only. The problem resides in contrast decreasing which makes almost impossible for the visualization of the small vessels.

REFERENCES

1. **P. J. Kilner, T. Geva, H. Kaemmerer, P. T. Trindade, J. Schwitter, and G. D. Webb**, "Recommendations for cardiovascular magnetic resonance in adults with congenital heart disease from the respective working groups of the European society of cardiology," *Eur. Heart J.*, vol. 31, pp. 794–805, 2010.
2. **J. Heautot, E. Chabert, Y. Gandon, S. Croci, R. Romeas, R. Campagnolo, B. Chereul, J. Scarabin, and M. Carsin**, "Analysis of cerebro vascular diseases by a new 3-dimensional computerised X-ray angiography system," *Neuroradiology*, vol. 40, pp. 203–209, 1998.
3. **Q. Yang, K. Li, X. Liu, X. Bi, Z. Liu, J. An, A. Zhang, R. Jerecic, and D. Li**, "Contrast-enhanced whole-heart coronary magnetic resonance angiography at 3.0T.A comparative study with X-ray angiography in a single center," *J. Amer. College Cardiol.*, vol. 54, pp. 69–76, 2009.
4. **A.Matsui, B. T. Lee, J. H.Winer, V. Kianzad, and J. V. Frangioni**, "Imageguided perforator flap design using invisible near-infrared light and validation with X-ray angiography," *Ann. Plastic Surg.*, vol. 63, pp. 327–330, 2009.